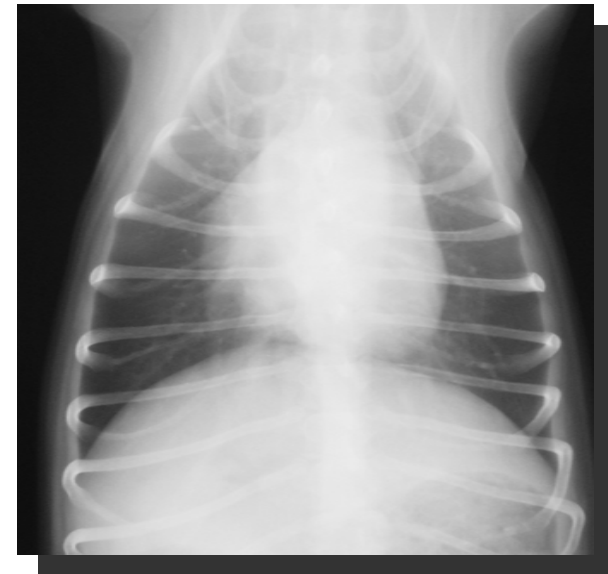



Thoracic X-Ray: Normal aspects

Nicole Van Israël
Animal CARDioPULmonary COnsultancy

DORSO VENTRAL (DV)

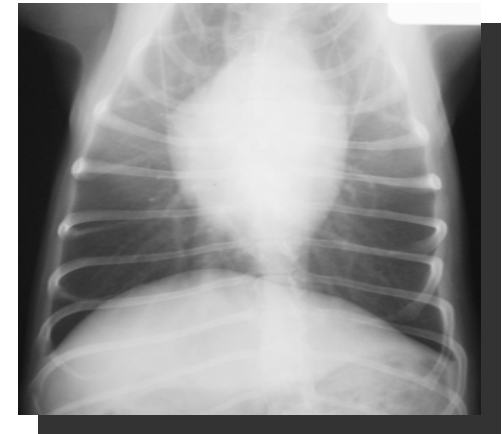- A single smooth curve of the diaphragm
- Gas within the stomach fundus on the left
- Overall less lung fields are seen due to forward bulging of the diaphragm
- Caudal lobar pulmonary vessels are readily seen
- Cardiac silhouette maintains a more physiological upright position



[Click to enlarge](#)

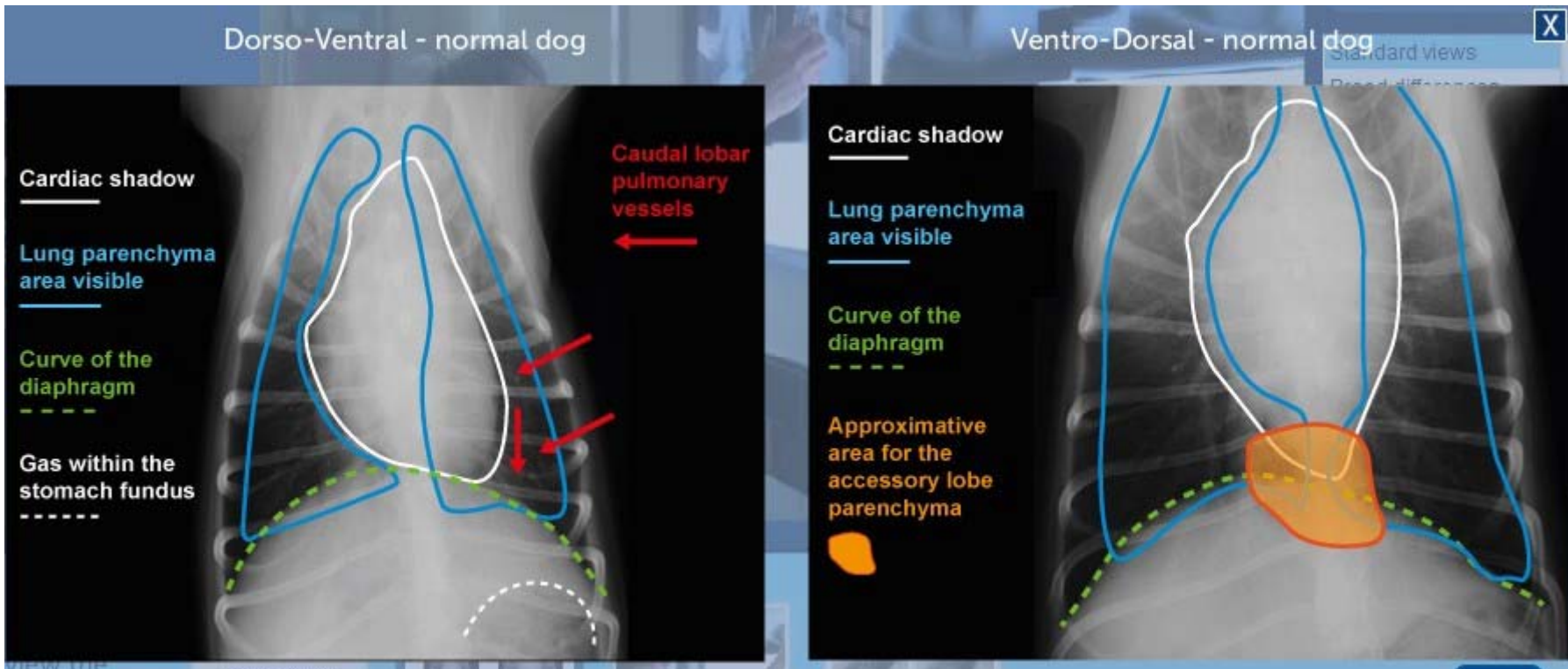
VENTRO DORSAL (VD)

- Crura are superimposed on the cupula giving a Mickey Mouse ears' appearance
- Gas present within the stomach body (middle) or pylorus (right side)
- Lung fields are better visible including the accessory lobe
- Caudal lobar pulmonary vessels not easily seen
- Cardiac silhouette flips over and appears elongated, often with an obvious pulmonary artery bulge



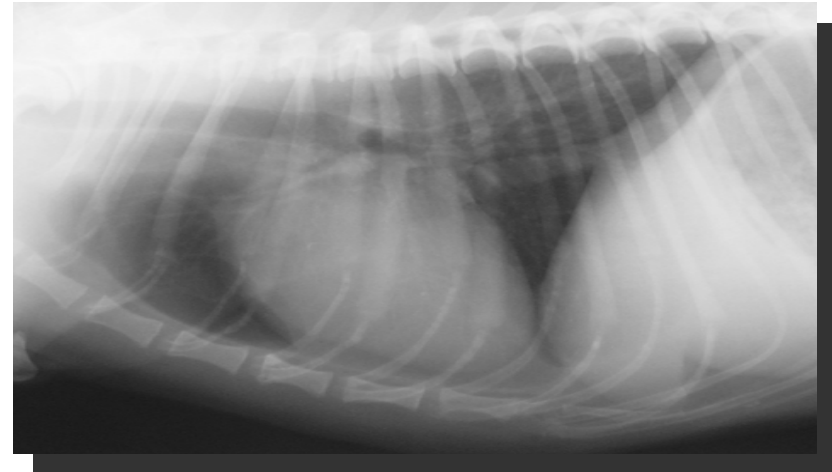
[Click to enlarge](#)

Differences between a Dorso-Ventral and a Ventro-Dorsal view – Normal dog



RIGHT LATERAL (RL)

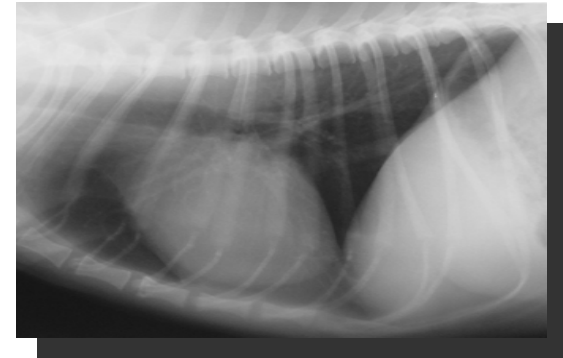
- The diaphragmatic crura lie parallel
- CVC merges with most cranial crus
- Left lung is more visible
- Cardiac silhouette is ovoid
- Cranial lobar pulmonary vessels overlap more easily



[Click to enlarge](#)

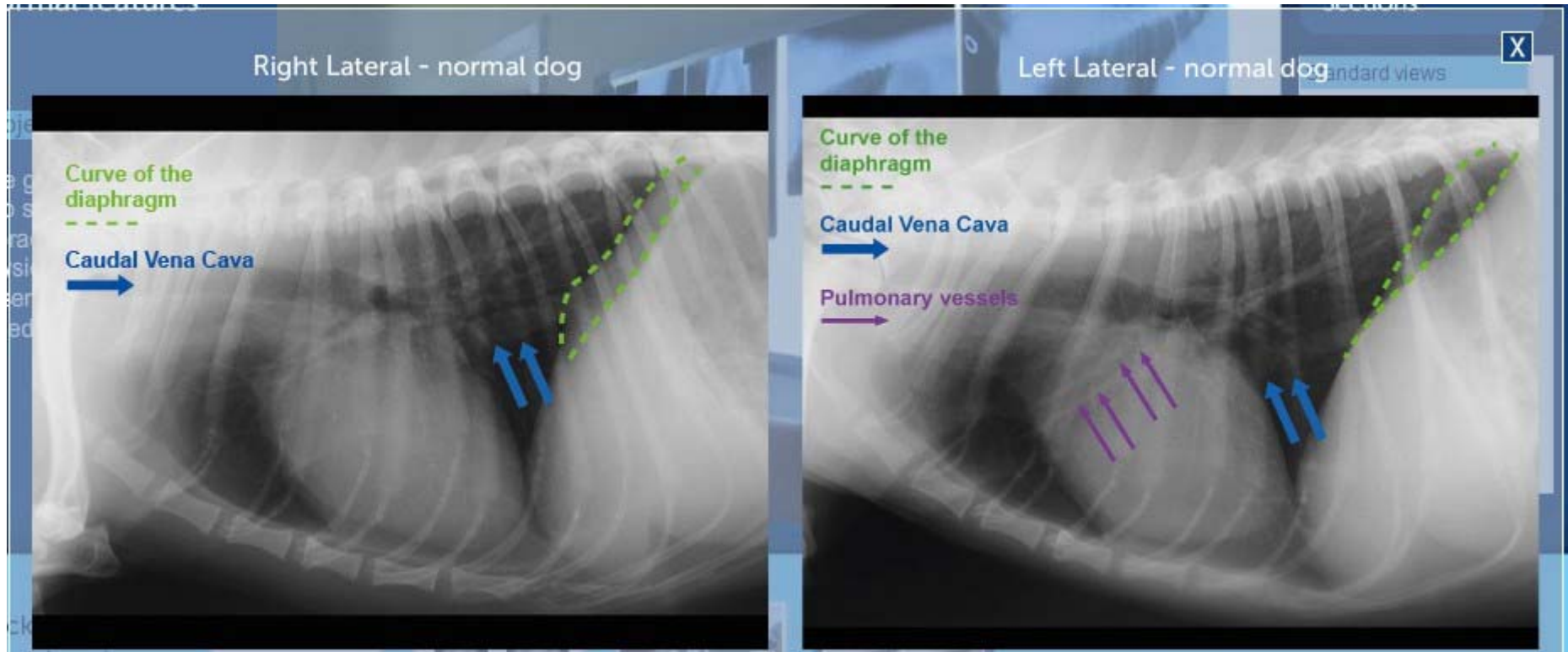
LEFT LATERAL (LL)

- The diaphragmatic crura are Y shaped
- CVC passes the most cranial crus
- Right lung is more visible
- Cardiac silhouette is more rounded (and might be elevated from the sternum)
- Cranial lobar pulmonary vessels overlap are easier to distinguish (often two pairs are visible)



[Click to enlarge](#)

Differences between a Right-Lateral and a Left-Lateral view – Normal dog

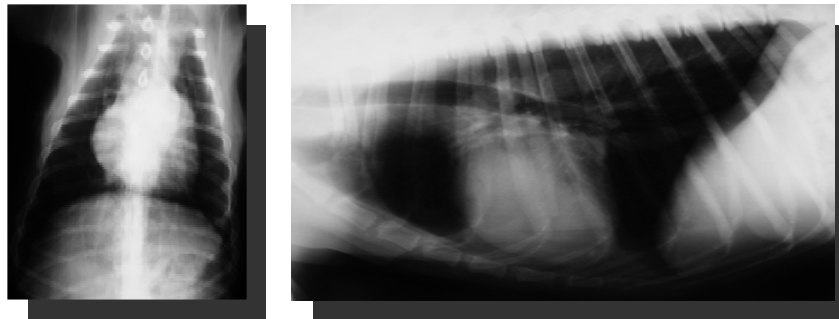


CARDIAC SHADOW

- Breed differences: thorax types
 - Wide shallow (brachycephalics, terriers,...)
 - Deep narrow (Irish Setter, Sighthounds,...)
 - Intermediate (GSD, Lab, GR, ...)

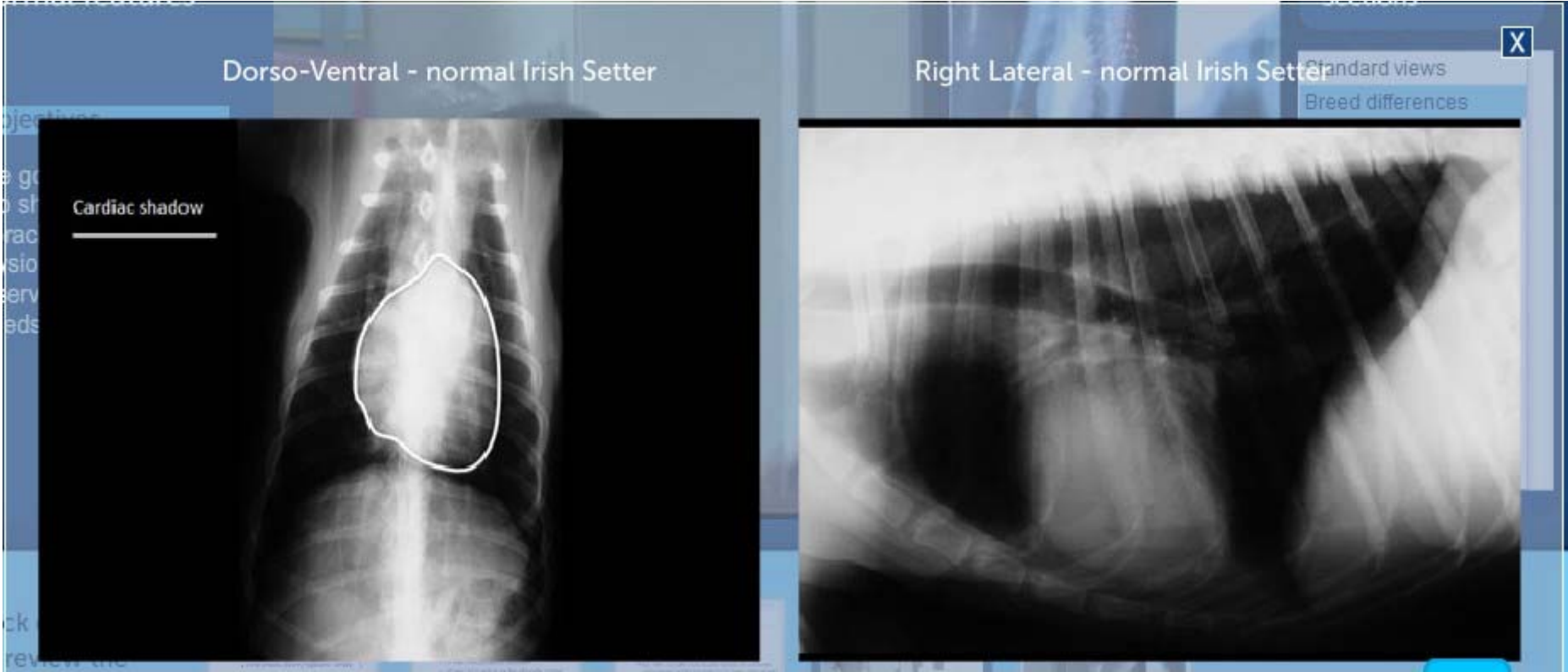CARDIAC SHADOW : BREEDS

- Deep narrow (Irish Setter, Dobies, Sighthounds,...)
 - DV view: circular cardiac silhouette
 - Lat view: long vertical cardiac silhouette contact



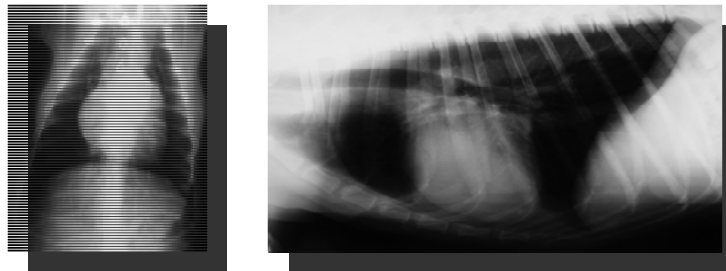
Dorso-Ventral and Right-Lateral views Dolicephalic breed

For personal use only. © Ceva Santé animale S.A.

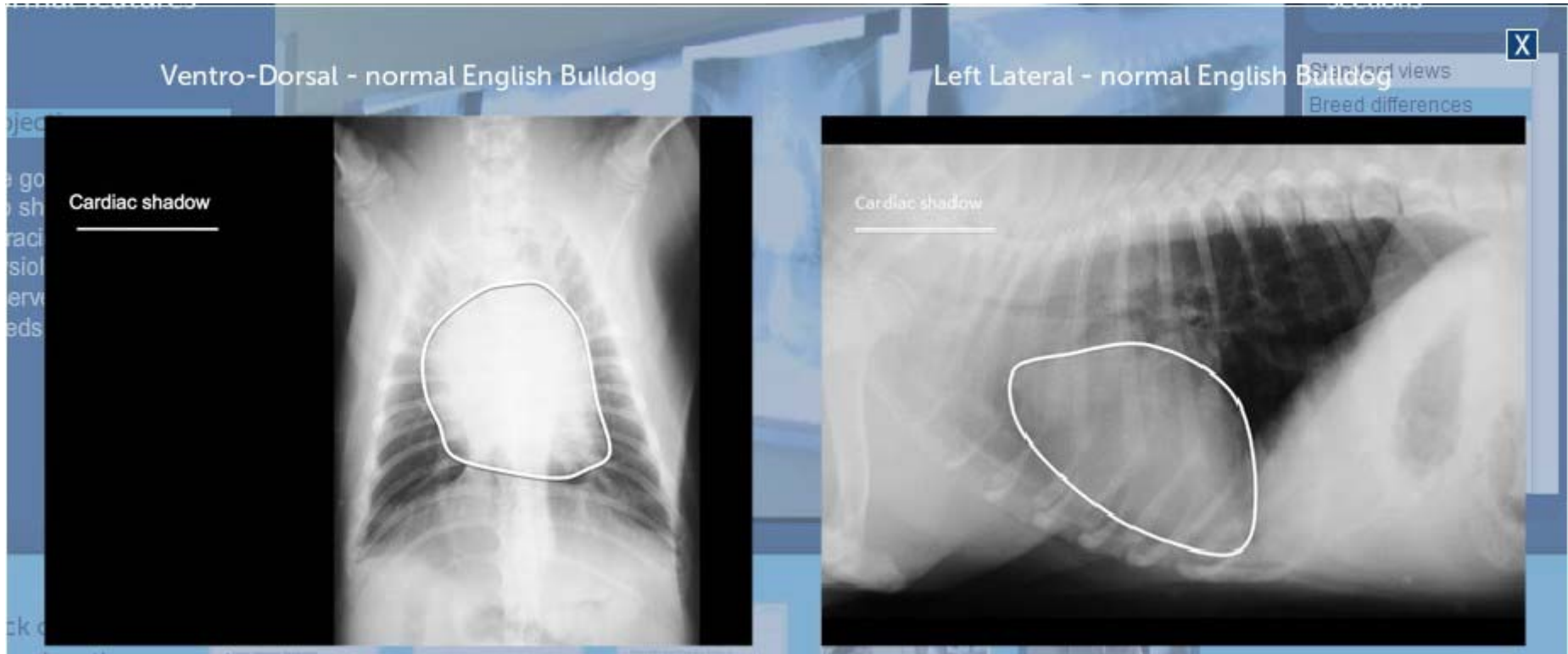


CARDIAC SHADOW : BREEDS

- Wide shallow (brachycephalics, terriers,...)
 - DV view : rounder cardiac silhouette
 - Lat view : rounder (more square) cardiac silhouette with more sternal contact (mimicking right-sided enlargement)



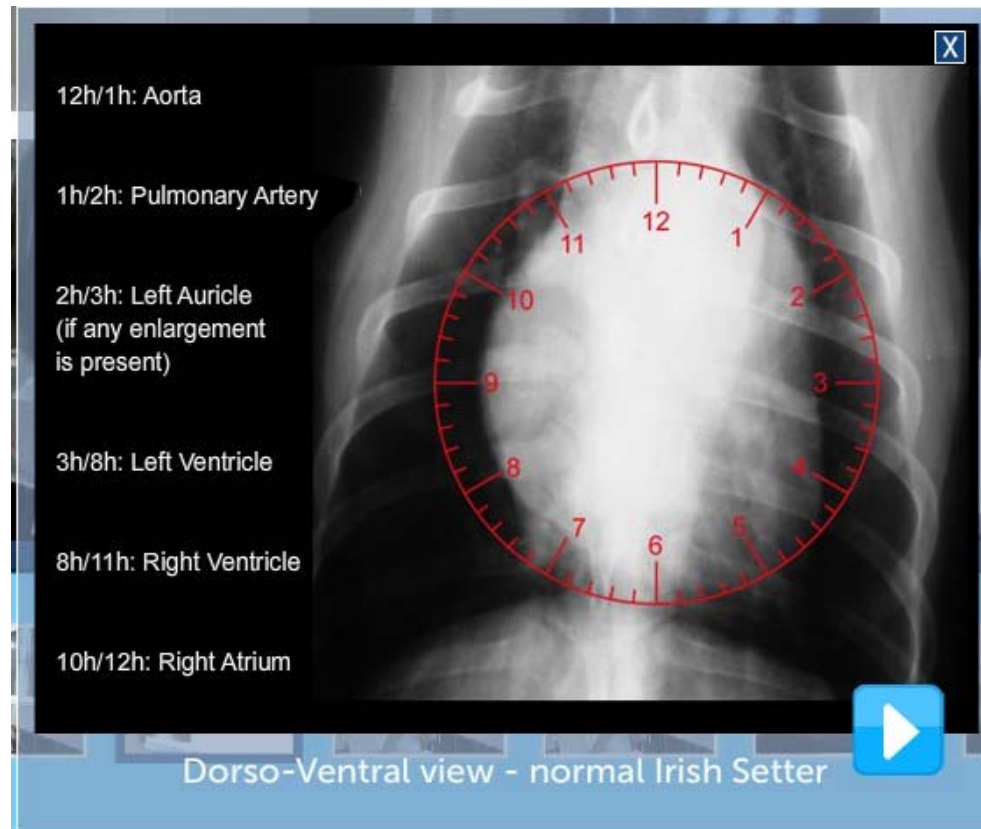
Ventro-Dorsal and Left-Lateral views Brachycephalic breed



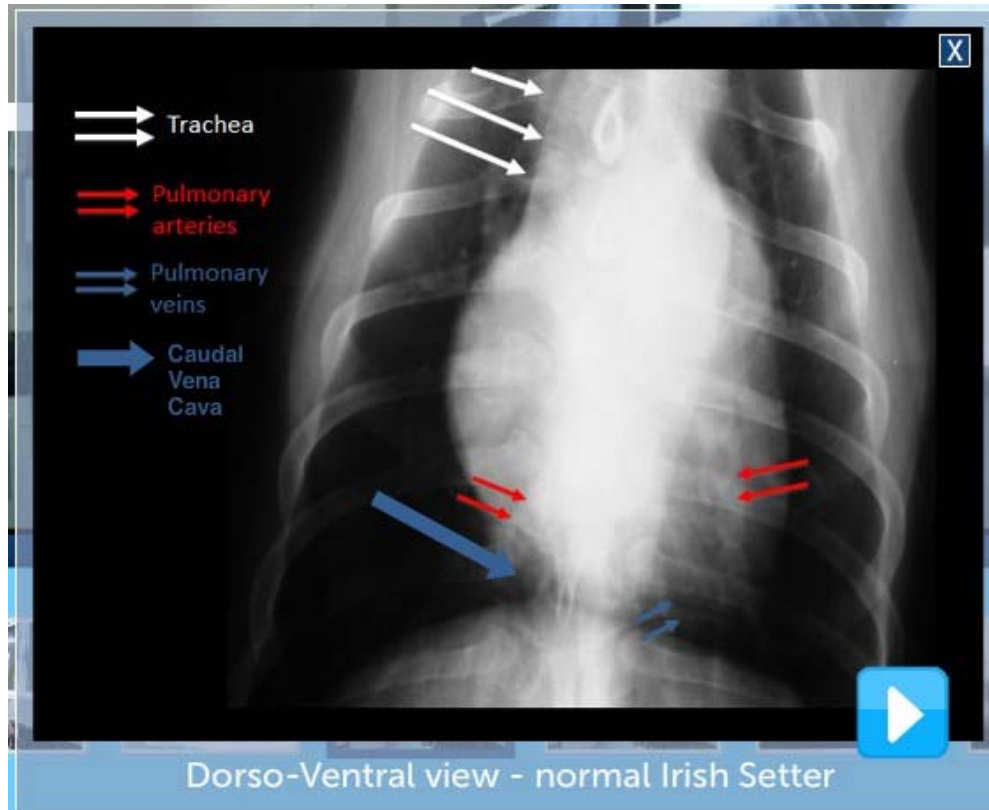
DORSO-VENTRAL VIEW DIFFERENT STRUCTURES



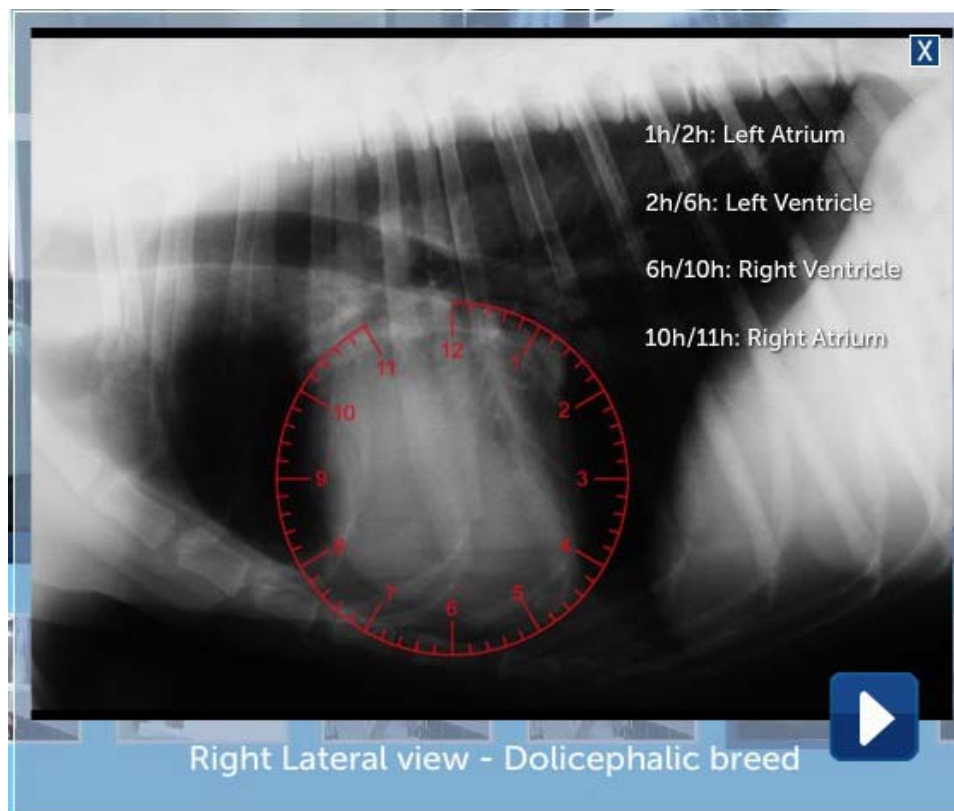DORSO-VENTRAL VIEW NORMAL CARDIAC STRUCTURES



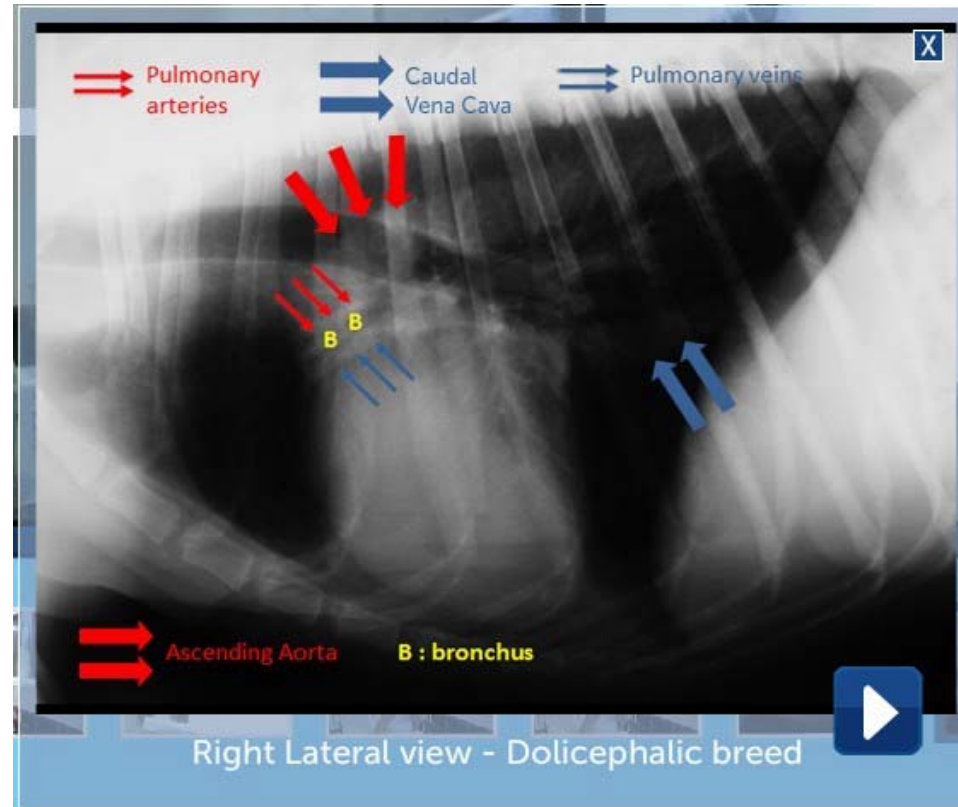
DORSO-VENTRAL VIEW NORMAL THORACIC STRUCTURES



RIGHT LATERAL VIEW NORMAL CARDIAC STRUCTURES



RIGHT LATERAL VIEW NORMAL THORACIC STRUCTURES



DORSO VENTRAL VIEW NORMAL THORACIC STRUCTURES

